ISPD

International Society of Pediatric Dermatology



ISPD News Bulletin

October 2026

Contents

The October 2026 issue of the International Society of Pediatric Dermatology (ISPD) News Bulletin includes:

Table of Contents

President's message **3**

Editor's Note **5**

Editorial **6**

ISPD Global Campaign **7**

Meeting reports **19**

Literature Review **21**

Our Sponsors **29**

1. President's Message:



Dear Colleagues and Friends,

As we approach the end of 2026, it is a pleasure to reflect on a year of meaningful progress, renewed commitment, and important achievements for the International Society of Pediatric Dermatology (ISPD). This year has been particularly significant as we embarked on our **ISPD Global Missions**, reaffirming our commitment to expanding access to pediatric dermatology education, strengthening international collaboration, and reaching colleagues and communities where educational resources and organizational support may be limited.

One of the major highlights has been the successful completion of our **three-level Pediatric Dermatology Course for Africa and the Middle East**. This initiative represents an important milestone in our Global Mission to spread pediatric dermatology education across the globe. The success of this program would not have been possible without the generous voluntary contributions of our BODs, international faculty, the dedication of our course directors, and the enthusiasm and active participation of colleagues from the participating regions. My sincere appreciation goes to everyone who contributed to making this educational initiative a success.



"A brief overview of the ISPD 2026 Pediatric Dermatology Course for Africa and Middle East"

Another important initiative was the **ISPD Atopic Dermatitis Awareness Campaign**, conducted throughout September in collaboration with our affiliated societies and partner organizations. This campaign provided an excellent opportunity to raise awareness about atopic dermatitis, promote better understanding of the disease, and strengthen our collective

efforts in supporting affected children and their families. I encourage you to go through the campaign report featured in this bulletin, which highlights the enthusiasm, collaboration, and achievements of the participating organizations.

In this issue, we are also pleased to feature an important editorial by our Board of Directors member and Editor, **Dr. Chika Olumukoro**, addressing the *Skin Manifestations of Ebola Virus Disease*. This is a particularly relevant contribution, reminding pediatric dermatologists of the importance of recognizing cutaneous manifestations of emerging and serious infectious diseases and understanding their potential diagnostic significance. Such knowledge is essential, particularly in regions where these infections may be encountered.

Furthermore, this bulletin brings you a report from the **International Society for Atopic Dermatitis (ISAD) Conference in Beijing, China**, along with our regular literature review, keeping our members informed about recent scientific developments and advances in pediatric dermatology and related fields.

As we look back on these achievements, I am particularly encouraged by the growing spirit of collaboration within our Society and the willingness of our members to contribute their expertise, time, and efforts towards our shared goals. These accomplishments reflect what we can achieve when we work together across geographical and professional boundaries.

Looking ahead, we hope to build on this momentum, expand our Global Missions, strengthen our partnerships with regional and affiliated societies, and continue creating meaningful educational opportunities for pediatric dermatologists worldwide.

In this spirit, I am pleased to announce our **2027 Pediatric Dermatology Course for the Balkan and Eastern European countries**, with a focus on regions where most needed. We look forward to sharing further details about this initiative in the coming months.

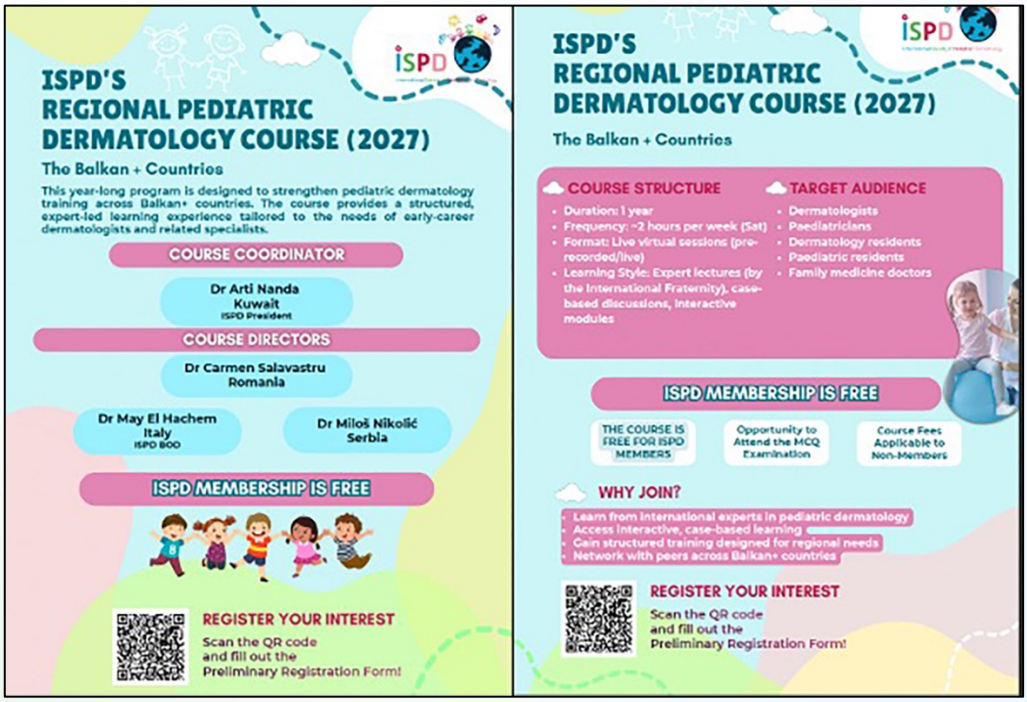

Together, let us continue to make pediatric dermatology education more accessible, strengthen our global community, and improve the quality of care for children with skin diseases everywhere.

Thank you to all our Board members, committee members, affiliated societies, international faculty, contributors, and members for your continued commitment and support.

With warm regards,

Arti Nanda, MD (President, ISPD)

2. Editor's Note:



The October 2026 issue of the ISPD News Bulletin brings together a rich collection of scientific updates, clinical insights and reports of academic activities from across the world, reflecting the continued growth and evolving scope of pediatric dermatology.

The editorial in this issue explores the cutaneous manifestations of Ebola virus disease, drawing attention to the importance of recognizing and documenting skin findings in serious systemic infections, particularly in children. A major highlight is the global observance of World Atopic Eczema Day, with enthusiastic participation from ISPD-affiliated societies and several institutions across different countries. This initiative reflects the spirit of international collaboration and our shared commitment to improving awareness, early diagnosis and care of children with atopic eczema.

The conference reports provide glimpses of important international academic meetings, including opportunities for scientific exchange, interaction and collaborative learning. The literature review covers a wide range of clinically relevant developments, including eczema associated with inborn errors of immunity, safety of systemic therapies in pediatric psoriasis, advances in alopecia areata, biomarkers in atopic dermatitis and emerging therapeutic approaches.

I hope readers will find this issue informative and engaging, and that it will encourage further academic interaction, research and collaboration in advancing the care of children with skin diseases.

Rahul Mahajan, MD (Editor, ISPD News Bulletin)

3. Editorial:



Beyond the Hemorrhage: Rethinking the Skin as a Diagnostic Mirror in Ebola Virus Disease

Ebola virus disease (EVD) is a severe systemic infection caused by viruses of the genus Ebolavirus, family Filoviridae. Human infection may follow animal-to-human spillover or direct contact with infectious bodily fluids of an infected person. Although EVD has historically been described as a hemorrhagic fever, overt bleeding is not present in all patients. Cutaneous manifestations, including a diffuse erythematous maculopapular rash and, in some patients, petechiae or ecchymoses, form part of the clinical spectrum. Their frequency and diagnostic significance, however, are incompletely characterized, particularly in children. This article considers what the available pediatric evidence establishes about skin findings in EVD and identifies areas where further dermatological documentation is needed. Following inoculation through mucosal surfaces or non-intact skin, Ebola virus targets cells of the mononuclear phagocyte system, including monocytes, macrophages and dendritic cells. Infected cells contribute to viral replication and dissemination. Viral immune-evasion mechanisms and the host inflammatory response contribute to systemic inflammation and organ injury (Dobbs et al., Pediatr Res. 2024;95:488-95).

Endothelial dysfunction, inflammation and coagulopathy contribute to vascular leakage and multiorgan injury in EVD. Hematological abnormalities are common, but overt hemorrhage is not universal. When bleeding occurs, reported manifestations include blood in the stool, petechiae, ecchymoses, oozing from venipuncture sites and mucosal hemorrhage (Dobbs et al., 2024). These findings are compatible with systemic vascular and coagulation disturbances. The precise mechanisms underlying individual skin lesions remain incompletely defined.

The clinical course of EVD includes an early phase of nonspecific febrile illness, commonly accompanied by chills, anorexia, headache and myalgia. A diffuse erythematous maculopapular rash may develop around days 5–7 and typically involves the face, neck, trunk and arms (Dobbs et al., 2024). Beyond this general description, detailed data on rash morphology, evolution and visibility across Fitzpatrick skin phototypes are lacking in children. The early clinical presentation overlaps with other infections, including malaria and viral infections common in childhood.

Hemorrhagic manifestations may occur during the course of EVD, but they are not universal and should not be assumed to follow a fixed timetable. In a retrospective cohort of 122 children with PCR-confirmed EVD admitted to treatment units in Liberia and Sierra Leone, bleeding was documented in 5% at triage and in 45% at some point during hospitalization. Non-hemorrhagic rash was recorded in 20% (22/112 in patients with data) during hospitalization (Smit et al., Clin Infect Dis. 2017;64:243-9). In a separate cohort of 91 children aged five years and younger in Sierra Leone, skin rash was documented in 6.6% (6/91) and bleeding in 15.4% (14/91) (Shah et al., Lancet Glob Health. 2016;4:e495-501). Differences between these estimates may reflect differences in age groups, settings and clinical documentation. The early symptoms of EVD are nonspecific and overlap with other infections,

including malaria and viral illnesses common in childhood (Dobbs et al., 2024). A maculopapular rash, when present, may contribute to the overall clinical assessment but cannot establish the diagnosis. Similarly, the absence of rash or bleeding does not exclude EVD. Clinical assessment must incorporate the epidemiological history and appropriate laboratory testing. Comparative dermatological data are insufficient to distinguish EVD from other viral hemorrhagic fevers, including the clinically similar Marburg virus disease, on skin findings alone; pathogen-specific laboratory testing is required for differentiation.

The presence of a rash alongside systemic symptoms may add to the clinical picture, but the available pediatric evidence does not show that skin findings reliably narrow the differential diagnosis or provide a validated early triage marker. In the absence of such evidence, cutaneous findings should be interpreted as one component of a broader clinical and epidemiological assessment, not as a basis for delaying isolation precautions or laboratory investigation. Human-to-human transmission of Ebolavirus is strongly associated with direct contact of mucous membranes or non-intact skin with infectious bodily fluids. Unbroken skin provides an important physical barrier. Infectious virus or viral RNA has also been detected in several body fluids, although the infectivity of virus detected in different fluids is not equally established (Dobbs et al., 2024). No good data exist on whether pre-existing dermatoses such as eczema or scabies, or PPE-associated dermatitis in health workers, alter the risk of acquiring EVD.

Cutaneous manifestations are an under-characterized component of EVD rather than established early diagnostic markers. Pediatric studies document maculopapular rash in a minority of patients and show that bleeding may emerge during hospitalization; bleeding was associated with higher odds of death in the cohort reported by Smit and colleagues. These observations support careful clinical documentation but do not establish a specific chronological evolution of skin lesions or the diagnostic sensitivity of dermatological examination. Future outbreak studies should record skin findings systematically, including morphology, distribution, timing, skin phototype and relationship to disease severity. Such data are needed before the diagnostic or prognostic value of individual cutaneous signs can be defined.

(Submitted by Chika Olomukoro, MD)

4. ISPD Global Campaign:

"World Atopic Eczema Day Awareness (September 2026), ISPD in Collaboration with Affiliated Societies & Organizations Across the Globe"

On the eve of **World Atopic Eczema Day (September 14, 2026)**, the International Society of Pediatric Dermatology (ISPD) extended a joint call to its affiliated societies and various organizations, inviting them to collaborate in raising awareness about the importance of early diagnosis, management, and improved care, with the ultimate goal of enhancing the quality of life and well-being of children living with atopic eczema across the globe. We were

delighted by the overwhelming response, with **eight affiliated societies and six independent organizations** joining the ISPD in this important mission.

Throughout the month of September, these societies and organizations conducted a wide range of activities across different parts of the world. These included patient awareness campaigns, distribution of educational materials, educational webinars for both healthcare professionals involved in the care of children with eczema and patients' families, as well as extensive awareness initiatives through social media. This collective effort reflects the power of collaboration and our shared commitment to making a meaningful difference in the lives of children affected by atopic eczema.

Together, we can transform the future of atopic eczema care and make it better than ever before!

A. Affiliated Societies

1. ISAD (International Society of Atopic Dermatitis)
2. ASPD (Asian Society of Pediatric Dermatology)
3. SDPL (Sociedad de Dermatología Pediátrica de Latinoamérica) – The Society of Pediatric Dermatology for Latin America
4. SIDerP (*Società Italiana di Dermatologia Pediatrica*) - The Italian Society of Pediatric Dermatology
5. Philippine Paediatric Dermatology Society & Philippine Dermatological Society
6. Kuwait Society of Dermatology
7. Saudi Dermatology Society
8. SES (Society for Eczema Studies) – India

B. Individual Organizations:

1. Bambino Gesù, OSPEDALE PEDIATRICO – IRCCS - Rome, Italy
2. Department of Pediatric Dermatology, Indira Gandhi Institute of Child Health, Bengaluru, India
3. DI Skin Hospital and Referral Center - Kathmandu, Nepal
4. Treichville University Hospital, Abidjan, Ivory Coast, West Africa
5. Paller Lab. Dermatology Clinical Trials Unit, Chicago
6. Department of Dermatology, PGIMER, Chandigarh, India

C. The Faculty who Actively Participated:

- **Officers & Board of Directors, ISPD**
  1. Arti Nanda (Kuwait) – President, ISPD
  2. Sandipan Dhar (India) – Vice-President, ISPD
  3. Mark Koh (Singapore) – Secretary General, ISPD
  4. Amy Paller (USA) – Immediate Past President & BOD, ISPD
  5. Margarita Larralde (Argentina) – Immediate Past Vice-President & BOD, ISPD
  6. Maya ElHachem (Italy) – BOD, ISPD
- **ISPD Editorial Staff (Committee Members):**
  1. Sahana Srinivas (India)

2. Wilsie Salas-Walinsunsin (Philippines)
3. Camelia Faye R. Tuazon (Philippines)
4. Smita Joshi (Nepal)
5. Rahul Mahajan (India)
6. Paula Boggio (Argentina)
7. Ahogo Kouadio Celestin (Ivory Coast, West Africa)

- **International Faculty:**
  1. Alain Taieb – President, Société Française de Dermatologie Pédiatrique (SFDP)
  2. Ruaa AlHarithy - Secretary General, Saudi Dermatology Society, KSA
  3. Domenico Bonamonte –President, SIDerP (Italian Society of Pediatric Dermatology)
  4. Dipankar De - Editor-in-Chief, Indian Dermatology Online Journal
  5. Jasmin Jamora – President, Philippines Dermatological Society
  6. Angela Esguera – President, Paediatric Dermatology Society Philippines
  7. Dr. Atlal AlLafi – Chairman, Dermatology Council Kuwait
  8. Abeer Bazali – President, Kuwait Society of Dermatology

Submitted by Arti Nanda, MD (President, ISPD)



"Department of Pediatric Dermatology, Indira Gandhi Institute of Child Health, - Bengaluru, India"



"SPDL (Sociedad de Dermatología Pediátrica de Latinoamérica) – The Society of Pediatric Dermatology for Latin America"







"Treichville University Hospital, Abidjan, Ivory Coast, West Africa"




"DI Skin Hospital and Referral Center - Kathmandu, Nepal"





"SES (Society for Eczema Studies) – Kolkata, India"





"Paller Lab. Dermatology Clinical Trials Unit, Chicago, USA"





"Department of Dermatology, PGIMER, Chandigarh, India"



"International Society of Pediatric Dermatology (ISPD)"



"International Society of Pediatric Dermatology (ISPD) + International Society of Atopic Dermatitis (ISAD)"

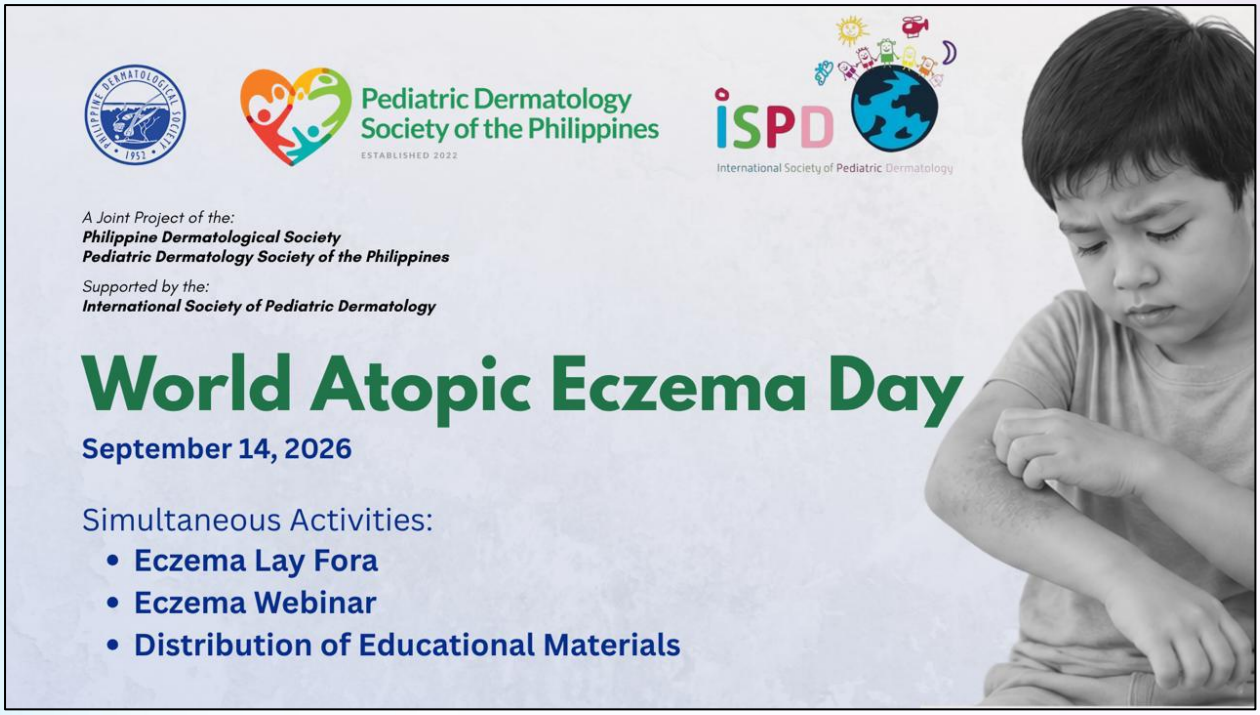

"ISPD + Philippines Dermatological Society + Pediatric Dermatology Society of Philipine"





"ISPD + ISAD + Asian Society of Pediatric Dermatology (ASPD), Singapore"



"ISPD + ISAD + Asian Society of Pediatric Dermatology (ASPD), Singapore"



"ISPD + Society for Eczema Studies (SES - India)"



"ISPD + Kuwait Society of Dermatology (KSD), Kuwait"



"ISPD + Italian Society of Paediatric Dermatology & Bambino Gesù Pediatric Hospital, Italy"



"ISPD + Saudi Society of Dermatology and Dermatology Surgery (SSDDS)"



"ISPD + Latin American Society of Pediatric Dermatology (SDPL), Argentina"



"ISPD + Pediatric Dermatology Dept., Indira Gandhi Institute of Child health, Bengaluru, India"

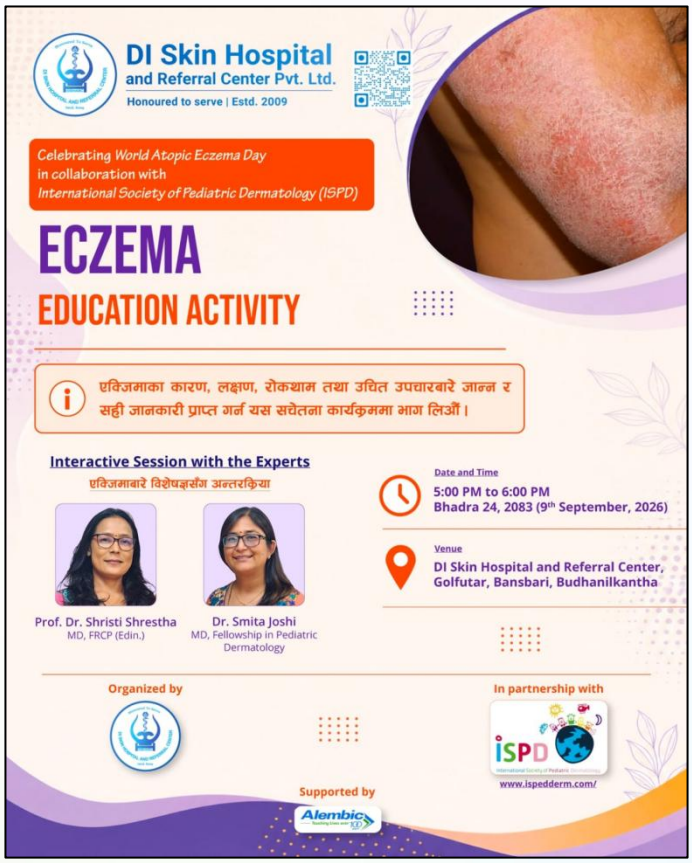

"ISPD + DI Skin Hospital and Referral Center - Kathmandu, Nepal"



"ISPD + Treichville University Hospital, Abidjan, Ivory Coast, West Africa"



"ISPD + department of Dermatology, Postgraduate Institute of Medical Education and Research (PGIMER), Chandigarh, India"

5. Meeting Reports

16th Georg Rajka International Symposium on Atopic Dermatitis (ISAD) Conference, Beijing, China.

It was a privilege to participate in the 16th Georg Rajka International Symposium on Atopic Dermatitis (ISAD) Conference held in Beijing, China. From the ISPD-BODs, Dr Sandipan Dhar, Dr Kin Fon Leong, and Dr Antoinette Chateau were invited to attend the WHO meeting, which brought together international experts to discuss strategies for optimizing the management of atopic dermatitis. During the ISAD Conference, Dr Dhar delivered a keynote lecture, presented two workshop sessions, and chaired and coordinated a workshop on behalf of the Asia Pacific Atopic Dermatitis Task Force (APADTF). Dr Chateau contributed to the development of the African Atopic Dermatitis Guidelines, an initiative spearheaded by the African Society of Dermatology and Venereology (ASDV).



"Leong Kin Fon (BOD, ISPD), Antoinette Chateau (BOD, ISPD), Sandipan Dhar (Vice-President, ISPD) in the 16th Georg Rajka International Symposium on Atopic Dermatitis (ISAD) Conference, Beijing, China"



"WHO Day "



"Sandipan Dhar, Presenting his lecture"

Submitted by Antoinette Chateau, MD (ISPD, BOD)

6. Pediatric Dermatology Literature Review:

Aubert H, Mahlaoui N, Barbarot S, et al. Eczema in inborn errors of immunity with atopy: frequency, timing, phenotypic clustering. Br J Dermatol. 2026. doi: 10.1093/bjd/ljag308.

This retrospective national registry study characterizes the frequency, clinical phenotypes, and temporal dynamics of eczema in patients with inborn errors of immunity with atopy (IEIs-A). By analyzing 373 IEIs-A patients from the French national IEI (CEREDIH) database, the authors found that over half (50.9%) of the cohort developed eczema, with an exceptionally high prevalence in those with DOCK8 (100%) and STAT3-LoF (74.6%) mutations. Crucially, the study demonstrated that eczema often appears early in life (median onset of 4 months) and can precede severe or unusual immunodeficiency-related infections by several years. The researchers identified four distinct clinical clusters, revealing that while some cases mimic classic atopic dermatitis, others display atypical features such as severe pruritus with buttock, genital, or palmoplantar involvement. Clinically, these findings underscore the necessity for dermatologists and pediatricians to recognize these distinct phenotypic patterns to avoid delayed IEIs-A diagnosis. Moving forward, recognizing eczema as an early warning sign of IEIs-A can guide timely immunologic investigations, enabling earlier targeted interventions such as systemic therapies for optimal multidisciplinary care.

(Submitted by Peter Yu Yu)

Bright HRB, McPherson T, Smith CH, et al. Serious infections in children and young people with psoriasis on systemic treatments. Br J Dermatol. 2026 Sep 18;195:691-693. doi: 10.1093/bjd/ljag306.

This case series and cohort analysis evaluates the long-term risk and clinical course of serious infections in children receiving systemic treatments for psoriasis, utilizing data from the British Association of Dermatologists Biologics and Immunomodulators Register (BADBIR). The most frequently used treatments were adalimumab (n=98), methotrexate (n=88) and ustekinumab (n=78). Other treatments included acitretin, apremilast, bimekizumab, brodalumab, certolizumab, ciclosporin, etanercept, guselkumab, infliximab, ixekizumab, risankizumab, secukinumab and tildrakizumab. The study followed 161 eligible children (contributing 414 treatment episodes) for an average of nearly two years, discovering that 20 patients experienced 24 serious infection events, translating to a low incidence rate of 31.42 per 1000 patient-years. Most infections were skin-related or respiratory, and while hospitalization was required (typically 2-4 days), there were no life-threatening complications or mortalities. Clinically, this report highlights the favorable long-term safety profile of both traditional and newer systemic treatments (such as IL-17 and IL-23 inhibitors) in pediatric psoriasis. Moving forward, the authors emphasize the importance of careful monitoring for recurrent infections and underlying comorbidities, affirming that while serious infections are clinically significant, they remain manageable and rare.

(Submitted by Peter Yu Yu)

Tao K, Miao Y, Hu R, et al. Upadacitinib for the treatment of refractory alopecia areata in pediatric patients: A retrospective study. J Am Acad Dermatol. 2026;94:1228-1230.

This retrospective study assesses the efficacy and safety of upadacitinib, a selective JAK1 inhibitor, in treating refractory alopecia areata (AA) among a pediatric cohort aged 6 to 11 years. Reviewing the medical records of 12 patients who failed prior systemic therapies—including corticosteroids and other JAK inhibitors—the authors observed significant clinical improvement over a 24-week period. At week 24, half of the patients achieved a Severity of Alopecia Tool (SALT) score of 20 or less, and 41.7% achieved a SALT score of 10 or less, alongside noticeable eyebrow, eyelash, and nail recovery in a subset of individuals. The treatment was generally well-tolerated, with only mild adverse events such as folliculitis and upper respiratory infections reported in a minority of cases. Clinically, this report indicates that upadacitinib serves as a viable and effective therapeutic option for young children burdened by severe, treatment-resistant AA. Moving forward, the authors emphasize the need for larger prospective studies to confirm these preliminary findings, while suggesting that factors such as baseline IgE levels and disease duration could help predict treatment outcomes in pediatric populations.

(Submitted by Peter Yu Yu)

Li Z, Li Y. Pediatric atopic dermatitis: biomarker advances in severity, persistence, and non-invasive monitoring. Front Pediatr. 2026;14:1902799.

Currently available severity assessment for atopic dermatitis (AD) heavily relies on clinical scoring systems limited by their subjective variations and inability to differentiate patient endotypes. Childhood AD differs from its adult counterpart due to significantly upregulated Th9 and Th17 response in the former as compared to Th22 response in the latter. Similarly, Asian AD shows mixed phenotype of eczema and psoriasis, with upregulated Th17 and Th22 response and lower Th1 response. These immunological differences, along with the availability of novel targeted therapies in AD, highlight the need for biomarkers focusing on pediatric AD. Severity biomarkers for AD can be categorized into several groups: TARC/CCL17 has been consistently validated as the most reliable severity marker across multiple studies; periostin has shown correlations with EASI and pruritus scores; eosinophil counts and total IgE have clinical utility in specific contexts (e.g., distinguishing extrinsic from intrinsic AD), but eosinophils have limited sensitivity in intrinsic AD, while IgE, in addition to this issue, also has poor specificity and weak correlation with severity; CCL26, SCCA2, and LDH show promise but require large-scale validation; IL-36 has preliminary evidence, but the discordance between mRNA and protein levels warrants further investigation; IL-8 has been shown in tape-stripping studies to correlate with local inflammation severity and treatment response.

From disease persistence standpoint, *FLG* mutations have the strongest genetic evidence, increasing the risk of multiple comorbidities by 2- to 3-fold and being closely associated with asthma, food allergy, and the atopic march; VEGF is a component of a combined prediction model and requires combination with clinical factors (SCORAD at 3 years of age, trigger factors), whereas S100A8/A9 is only effective in FLG wild-type infants; skin lipid markers demonstrate the best predictive performance (89.4% accuracy for a combination of five lipid ratios); barrier function measures (NMF, TEWL) and barrier composition markers (ceramides,

phytosphingosine) can help identify early skin barrier abnormalities, although the consistency of TEWL measurements across studies is limited.

Non-invasive biomarker detection techniques such as tape stripping, sebum RNA monitoring and hyaluronic acid microneedles in contrast to the traditional minimally invasive skin biopsies and blood samples are expected to play a more important role in the early diagnosis and disease monitoring of pediatric AD research. Despite the significant advances, most biomarkers still lack pediatric specific cutoffs and need large scale validation. In conclusion, availability of multi-marker panels, pediatric reference intervals and access to endotype classification through biomarkers, can aid in valuable research that could eventually translate into clinically meaningful personalized management of pediatric AD.

(Submitted by Smita Joshi)

Vroman F, de Graaf M. The era of advanced therapeutics for pediatric atopic dermatitis - can early systemic intervention reduce the type 2 inflammatory response and modify the atopic march? Curr Opin Pediatr. 2026;38:402-408.

Atopic dermatitis (AD) is chronic disease in which early disease severity emerges as a potentially modifiable factor to a more prolonged disease course. Additionally, AD is often considered the first manifestation of the atopic march; early intervention may provide an opportunity to alter the natural course of further development of allergic diseases.

An emerging hypothesis suggests that early therapeutic intervention could endurably impact the natural course of AD by altering the underlying Th2-mediated pathways leading to sustained remission and attenuation of the atopic march. This concept is commonly referred to as disease modification (DM). DM in inflammatory skin disorders such as AD should consider two main aspects: the impact on the disease itself, (i.e. the chronic inflammation in the skin), and the impact on the associated comorbidities, (i.e. the atopic march). Thus, DM in AD can be defined as the therapeutic interventions with an aim of achieving prolonged remission or sustained reduction in disease severity after treatment discontinuation, and/or reducing the risk of new-onset AD-related comorbidities, with or without ongoing treatment.

Currently, no therapies for AD have been recognized as disease-modifying by regulatory agencies. Studies on the use of topical corticosteroids have shown that proactive treatment may lead to a lower risk of developing a food allergy, suggesting that the promptness with which AD patients are treated can influence both the course of the disease and the development of allergic comorbidities, the so called ‘window of opportunity’. It is assumed that there is a window of time at the very early stages of AD during which DM may be possible, but it is unclear when and how long this window lasts.

At this time, both biologics (dupilumab, tralokinumab, and lebrikizumab) and Janus kinase (JAK) inhibitors (baricitinib, abrocitinib, and upadacitinib) are available for treating pediatric AD, of which the majority is only approved from the age of 12 years. Amongst these interventions, recent literature suggests that dupilumab is a promising disease-modifying treatment option. A meta-analysis reported a 34% reduction in new allergies in patients over 12 years old, which persisted even during off-treatment periods. Other studies showed that patients on dupilumab treatment had a significant decreased risk of developing the atopic march towards asthma or AR compared with patients on conventional systemic therapy. This

effect was even more pronounced in younger children, highlighting the importance of the window of opportunity. Dupilumab also shows the possibility of AD remission after treatment discontinuation. Earlier presentation of preliminary data from pediatric patients showed that approximately one-third of patients achieved clinical remission, with half of them remaining therapy-free. Current evidence on the potential for attenuation of atopic march and achieving disease remission is limited for tralokinumab, lebrikizumab, JAK inhibitors and OX40 inhibitors.

The definition of DM in AD is complicated by the variable course of AD and its high rate for spontaneous remission, especially in young children. In conclusion, as the systemic treatment options become increasing available to treat pediatric AD, their potential impact on long term disease remission and atopic march should be further investigated to outline the window of opportunity and eventually make DM in AD, a defined therapeutic strategy.

(Submitted by Smita Joshi)

Sengkioun OA, Yücelten D, Ergun T. Ustekinumab as an Effective Therapeutic Option in Papillon-Lefèvre Syndrome: Long-Term Follow-Up. Pediatr Dermatol. 2026 Sep 2. doi: 10.1111/pde.70351.

Papillon-Lefèvre syndrome (PLS) is a rare autosomal recessive genodermatosis characterized by palmoplantar hyperkeratosis and severe periodontitis, leading to premature loss of both primary and permanent teeth, and treatment responses are often unsatisfactory. The authors report a 20-year-old female patient with PLS who presented with extensive palmoplantar hyperkeratosis and widespread psoriasiform plaques refractory to multiple conventional therapies. Treatment with ustekinumab resulted in marked clinical improvement by the sixth month after three subcutaneous injections. The patient has remained in sustained clinical remission during 6 years of continuous therapy, with only mild and intermittent recurrent plaques on the knees, suggesting that biologic therapy may represent a sustainable option in selected cases of PLS.

(Submitted by Anwar Al-Sumait, MD)

Hebert AA, Guide SV, Groysman V, Gonzalez ME, Blanco D, Laquer V, et al. Early Evidence of Safety, Clinical Benefit, and Pharmacokinetics of Roflumilast Cream 0.3% Once Daily for Treatment of Mild or Moderate Plaque Psoriasis in Children Aged 2-11 Years. Pediatr Dermatol. 2026 Jan-Feb;43:105-108. doi: 10.1111/pde.70013.

Two 4-week, phase 2, open-label, maximal usage pharmacokinetic (PK) and safety studies of once-daily roflumilast cream 0.3% (a potent phosphodiesterase 4 inhibitor) were conducted in children aged 2-5 years and 6-11 years with psoriasis. Caregivers applied roflumilast to affected areas once daily for 28 days. Evidence of systemic exposure to roflumilast and its active N-oxide metabolite was seen in most patients following daily application, consistent with previous studies. One patient in the 2–5 years study reported a treatment-emergent adverse event (TEAE; headache, mild). Four patients in the 6–11 years study reported a total of eight mild TEAEs (application-site pain, candida infection; back pain and headache; and dermatitis, nasal congestion, perineal erythema, and perineal pain. No TEAE led to discontinuation. Investigators reported no signs of irritation for 100% of patients aged 2–5 years and ≥ 85% of patients aged 6–11 years. Under maximal use conditions, once-daily

roflumilast cream 0.3% was well tolerated and improved signs and symptoms of psoriasis in children aged 2-11 years, consistent with phase 3 results in adults and adolescents.

(Submitted by Anwar Al-Sumait, MD)

Chang S, Zhang L, Liu B, et al. Efficacy of oral JAK inhibitors combined with 308-nm excimer laser in pediatric progressive vitiligo: A multicenter study. J Am Acad Dermatol 2026;94:1731-37.

Treatment options for progressive vitiligo in children are limited, with current therapies often lacking sustained efficacy and safety. To evaluate the efficacy and safety of Janus kinase inhibitor combined with 308-nm excimer laser therapy in children with progressive vitiligo. This multicenter, prospective, single-blind randomized controlled trial enrolled 188 children aged 2∼18 years with progressive vitiligo who received treatment for 48 weeks. Group A received an oral Janus kinase inhibitor combined with 308-nm excimer laser therapy, while Group B received topical tacrolimus combined with 308-nm excimer laser therapy. The primary outcome was the rate of repigmentation assessed by the Vitiligo Area Scoring Index. Group A exhibited significantly higher repigmentation rates than Group B ($P < .001$), with mild to moderate adverse events and good tolerability. Treatment response was correlated with age, disease duration, lesion location, and follicular depigmentation. The single-blind design, limited sample size and follow-up, and single comparator restrict generalizability regarding long-term efficacy and safety.

(Submitted by Anwar Al-Sumait, MD)

Eichenfield LF, Serrao R, Prajapati VH, et al. Efficacy and Safety of Once-Daily Roflumilast Cream 0.05% in Pediatric Patients Aged 2–5 Years with Mild-to-Moderate Atopic Dermatitis (INTEGUMENT-PED): A Phase 3 Randomized Controlled Trial. Pediatric Dermatology. 2025;42:296–304.

Atopic dermatitis (AD) is a chronic inflammatory skin disease associated with pruritus and other symptoms that can affect sleep and quality of life in children. Roflumilast is a topical phosphodiesterase-4 inhibitor formulated as a once-daily, water-based cream. The 0.05% concentration was evaluated in children aged 2–5 years because of their higher body-surface-area-to-body-mass ratio and potentially greater AD involvement. INTEGUMENT-PED was a 4-week, Phase 3, double-blind, vehicle-controlled randomized trial involving children aged 2–5 years with mild-to-moderate AD who were randomized 2:1 to once-daily roflumilast cream 0.05% or vehicle. Outcomes included vIGA-AD Success, EASI-75, WI-NRS Success, adverse events, and local tolerability. At Week 4, vIGA-AD Success was achieved by 25.4% of patients receiving roflumilast compared with 10.7% receiving vehicle, while EASI-75 was achieved by 39.4% versus 20.6%, respectively. WI-NRS Success was also greater with roflumilast (35.3% vs. 18.0%), with significant improvement in pruritus occurring within 24 hours of the first application. Adverse events were generally mild or moderate, and application-site discomfort was uncommon. These findings demonstrated early and clinically meaningful improvement in both AD signs and pruritus with favorable tolerability.

Once-daily roflumilast cream 0.05% was effective and well tolerated in children aged 2–5 years with mild-to-moderate AD, supporting its potential as a nonsteroidal topical treatment in this

age group; however, the authors noted that the short 4-week study duration warranted longer-term evaluation.

(Submitted by Wilsie Salas-Walinsudin, MD)

Eichenfield LF, Gonzalez ME, Boguniewicz M, et al. Long-Term Safety and Efficacy of Once-Daily and Proactive Twice-Weekly Roflumilast Cream 0.05% for Mild-to-Moderate Atopic Dermatitis in Children Aged 2–5 Years From a 52-Week, Phase 3 Trial (INTEGUMENT-OLE). Pediatric Dermatology. 2026;43:642–649.

INTEGUMENT-OLE directly continued the findings of INTEGUMENT-PED by evaluating the long-term safety and efficacy of roflumilast cream 0.05% in children aged 2–5 years with mild-to-moderate AD. Because AD is recurrent, proactive treatment of previously affected areas may help maintain disease control after clinical clearance. The study therefore examined continued once-daily treatment and the use of proactive twice-weekly treatment in patients who achieved clear skin. This Phase 3 open-label extension enrolled 562 children who had completed INTEGUMENT-PED, with roflumilast cream 0.05% applied once daily and patients achieving vIGA-AD 0 at or after Week 4 switching to twice-weekly application. Safety and application-site tolerability were the primary focus, while efficacy was assessed using vIGA-AD, EASI-75, WI-NRS, and duration of disease control. At Week 56, AD signs and symptoms continued to improve, with 63.1% of patients achieving vIGA-AD 0/1 and EASI-75 achieved by 71.9% of patients who continued roflumilast and 76.0% of those who switched from vehicle. WI-NRS Success also continued to improve, reaching 57.9% and 66.3%, respectively. Among the 562 patients, only 2.5% experienced treatment-related adverse events, and no treatment-related serious adverse events were reported. Importantly, 170 patients who achieved clear skin switched to proactive twice-weekly application, with a median duration of disease control of 238 days.

Long-term treatment with roflumilast cream 0.05% for up to 56 weeks demonstrated sustained efficacy and a favorable safety profile, while proactive twice-weekly treatment-maintained disease control for approximately 8 months, supporting its potential role as a long-term proactive, nonsteroidal treatment strategy for pediatric AD.

(Submitted by Wilsie Salas-Walinsudin, MD)

Chêne L, Hubiche T, De Guillebon J-M, et al. TNF Inhibitor Therapy in Corticosteroid-Resistant or -Dependent Pediatric Neutrophilic Dermatosis. Pediatric Dermatology.2026;43:373–377.

Neutrophilic dermatoses (NDs), particularly pyoderma gangrenosum (PG) and Sweet syndrome (SS), are rare in children and are characterized by sterile neutrophilic infiltrates in the skin. Pediatric cases may have severe presentations, including mucosal and upper-airway involvement. Systemic corticosteroids are considered first-line treatment, but there is limited guidance for children who are corticosteroid-resistant or corticosteroid-dependent. This study therefore describes the use of tumor necrosis factor inhibitors (TNFi) in five children with difficult-to-treat neutrophilic dermatoses. This was a retrospective multicenter study involving children aged ≤18 years with histologically confirmed PG or SS who either failed to respond to systemic corticosteroids at a minimum dose of 2 mg/kg/day or relapsed

when corticosteroids were reduced. Medical records were reviewed using a standardized questionnaire, and the study was registered with the Nice University Hospital treatment registry. Five children met the inclusion criteria: three with PG and two with SS.

All five children had painful pustular and/or necrotic cutaneous lesions, with two having severe mucosal involvement. Corticosteroids at doses of 2–5 mg/kg/day were either ineffective or resulted in steroid dependence, while previous treatments such as dapsone and cyclosporine were ineffective or limited by toxicity. TNFi therapy produced clinical improvement in all five patients: infliximab was used in three patients and adalimumab in three, including one patient switched from infliximab because of anti-drug antibodies. Systemic corticosteroids could be discontinued in three children within 1–6 months, while TNFi was discontinued in two children after complete response, with only limited relapses. No adverse effects were reported in this small cohort.

The authors note that TNFi appeared effective and well tolerated, consistent with previously reported pediatric experience, although optimal dosing may require higher or more frequent regimens in some children. In this series, infliximab was effective at doses up to 10 mg/kg every 2–3 weeks, while adalimumab was used at 20–40 mg every 1–2 weeks, depending on weight. A key limitation is the potential development of anti-drug antibodies, which caused treatment failure in one patient but allowed successful switching to another TNFi. The study is limited by its very small sample size and retrospective, descriptive design, and the authors emphasize that larger studies are needed.

TNF inhibitors may provide a rapidly effective and well-tolerated treatment option for children with corticosteroid-resistant or corticosteroid-dependent neutrophilic dermatoses. The five reported cases demonstrated improvement with infliximab and/or adalimumab and allowed corticosteroid withdrawal in several patients. However, the findings should be interpreted cautiously because of the small cohort and retrospective nature of the study.

(Submitted by Wilsie Salas-Walinsudin, MD)

O'Connor RJ, Visscher MO, Narendran V, et al. Clinical Evaluation of a Diaper Containing a Shea Butter-Based Emollient and Impact on Diapered Skin Erythema. Pediatric Dermatology.2025;42:532–538.

Diaper dermatitis is a common condition in infancy, primarily characterized by erythema resulting from repeated exposure of the diapered skin to moisture, friction, urine, fecal enzymes, and changes in skin pH. The diaper environment increases skin hydration and friction, making the skin more susceptible to mechanical and chemical injury. Emollients can provide a protective barrier that reduces direct contact between the skin and irritants, with petrolatum-based emollients (PBE) having a long history of prophylactic use. This study evaluated a shea butter-based emollient (SBE) incorporated into the diaper liner, hypothesizing that it would provide skin protection comparable to PBE and greater protection than a diaper without emollient. The study included an on-baby emollient transfer study, a 6-week randomized, blinded, crossover diaper-wear study, and two adult forearm models evaluating protection against sodium lauryl sulfate (SLS) irritation and overhydration. In the

diaper-wear study, 271 healthy babies wearing size-4 diapers first used a PBE-containing diaper for 3 weeks and were subsequently randomized to continue PBE (n=27), transition to SBE (n=123), or transition to a non-emollient diaper (n=121) for another 3 weeks. Erythema was assessed twice weekly at the genital, intertriginous, buttock, and perianal sites using a blinded 7-point clinical grading scale. The primary analyses evaluated the proportion of infants who remained erythema-free (score 0) and those who developed erythema ≥1.5.

Both SBE and PBE were transferred from the diaper to the infant's skin in measurable microgram quantities, with transfer increasing with continued diaper wear. Fluorescent visualization demonstrated distribution across the genital, buttock, intertriginous, and perianal regions, confirming that the diaper could serve as a vehicle for continuous emollient delivery. Clinically, infants transitioned from PBE to a non-emollient diaper demonstrated a significant increase in erythema at the genital (11.6%, $p<0.05$) and perianal (16.5%, $p<0.001$) sites, whereas transition from PBE to SBE produced no significant increase in erythema severity. The SBE diaper provided particularly notable protection at the perianal site, where infants were 2.6 times more likely to be erythema-free compared with those using the non-emollient diaper. The adult forearm models similarly demonstrated that both SBE and PBE reduced irritation and skin overhydration. These findings suggest that continuous, low-level emollient delivery directly from the diaper can preserve diapered-skin integrity while avoiding the potentially excessive amounts associated with manual application. The authors further note that no candidal infections occurred during the study, although the study did not evaluate infants with established or severe diaper dermatitis.

A disposable diaper containing an emollient provides greater protection against diaper-area erythema than a diaper without emollient. The shea butter-based formulation demonstrated efficacy comparable to the established petrolatum-based formulation and was well tolerated. The study supports diaper-integrated emollient delivery as a practical preventive barrier strategy for maintaining skin integrity and reducing diaper-area irritation. However, further research is needed to determine its effectiveness in infants with established or more severe diaper dermatitis.

(Submitted by Wilsie Salas-Walinsudin, MD)

Gottlieb S, Madkins K, Lio P. An Updated Scoping Review of Disparities in Pediatric Atopic Dermatitis. Pediatric Dermatology. 2025;42:457–468.

This updated scoping review examined health disparities in pediatric atopic dermatitis (AD) in the United States, with the goal of identifying persistent inequities and gaps in the literature. The authors conducted a systematic search following PRISMA guidelines, reviewing studies published from January 2021 to May 2024 across MEDLINE, Embase, and Cochrane databases; 53 studies met inclusion criteria. The majority of studies focused on race/ethnicity (49 studies) and socioeconomic status (18 studies), with additional research addressing region/environment, sex/gender, and preferred language. Overall, Black and Hispanic children and those from lower socioeconomic backgrounds experienced higher AD prevalence, greater comorbidities and healthcare utilization, poorer disease control, and greater barriers to timely and appropriate care, including delayed appointments, missed prescriptions, and transportation-related delays. The review also identified geographic and sex-related disparities, while emphasizing that race/ethnicity and socioeconomic status are

interrelated but should not be considered interchangeable explanations for inequities. The authors conclude that these disparities persist and call for health-equity interventions, improved access to dermatologic care, greater cultural competence and skin-of-color training, and further research involving understudied marginalized pediatric populations.

(Submitted by Wilsie Salas-Walinsudin, MD)

7. Sponsors:

We would like to thank our Industry partners for their support.

Gold Sponsor

Silver Sponsor

Bronze Sponsor